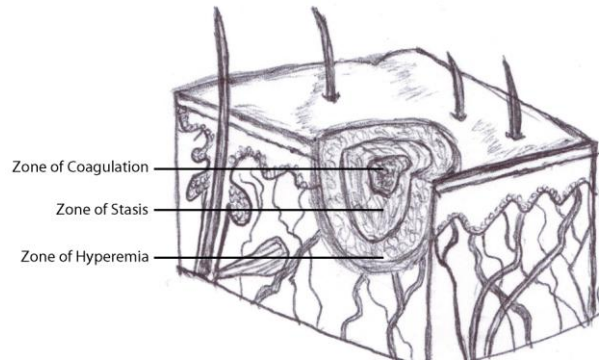


Acute Flame Burns

Pathophysiology:

- Skin → large water content → overheats and cools slowly + heat continues to penetrate deeper layers (immediate cooling can reduce this, limited in large burns b/c can lower pt's core temperature)
- 3 zones of injury:
 - Coagulation (central): nonviable + irreversible
 - Stasis (middle): Dilated vessels + capillary diffusion → in 24-48hrs can become occluded and convert into zone of coagulation OR reversed to viable tissue (cooling, fluids, acute care very important to save this area)
 - Hyperemia (outer): viable, edematous



- Circulation changes: initial increase in blood flow to area + arteriolar vasodilation (capillary permeability) → proteins leaked → edema (most at 8-12hrs) = “third-spacing”

Acute Management:

- History: source (flame, liquid, steam, chemical, electrical, etc), duration, location (closed space? → smoke inhalation), associated injuries/injury mechanism, intoxication (EtOH, drugs)
- ABCDE (stressing points associated w burns)
 - A: early intubation (airway edema esp with smoke inhalation; used humidified O2, bronchodilators to Tx spasm) *
 - B: maybe escharotomies for circumferential chest + abdominal wall burns
 - C: Large-bore (14-16G), ideally through non-burned tissues, central line
Fluids → RL***, no glucose (hyperglycemic b/c stress response → +++osmotic diuresis)
 - D: baseline neuro (may detect CO poisoning**, important if need to sedate)
 - E: remove clothes, irrigate w NS, cover w nonadherent drg. to prevent hypothermia
- * Inhalation injury:
 - Why: smoke chemical irritants (ARDS), thermal injury (oropharyngeal + supraglottic edema)
 - Signs: Closed space, facial burns, singed facial hair, oral carbon deposits, hoarseness, wheezing
 - Evaluate: Nasopharyngoscopy (larynx, vocal cords); +/- bronchoscopy
 - (Note: low threshold for ophthalmology consult for facial burns)
- **CO poisoning:
 - Why: Binds to hemoglobin → O2 displaced/does not bind → less O2 delivery to body
 - Signs: Cherry red skin, hypoxemia (pulse oxymetry unreliable → cannot distinguish between different forms of hemoglobin = carbo-xyhemoglobin registered as 90% oxygenated hemoglobin and 10% desaturated hemoglobin = overestimate the saturation), mental status change/depressed, persistent acidosis even if normovolemic; think cyanide toxicity (plastics)
 - Tx: 100% O2, hyperbaric therapy (esp if mental status change)
- ***Fluids:
 - Must repeatedly assess! No formula is perfect! → exam, urine output, central wedge pr., etc.
 - Parkland formula = (4cc) x (%TBSA) x (patient's weight in kg) for 24hrs
 - Half in 1st 8 hours, rest in remaining 16hrs
 - RL at first, consider colloids after 8hrs if ++ fluid requirements (can also decrease the risk of abdominal compartment syndrome)
 - Adequate resus? → urine output

- Adults 0.5cc/kg/hr; kids 1cc/kg/hr
- Need 2cc/kg/hr in electrical or deep burns (3rd deg. including muscle) → myoglobin-induced acute tubular necrosis (can also alkalinize urine w bicarbonate)
- Follow electrolytes: Hyponatremia, hyperkalemia

- Analgesia
- Tetanus:

Hx	Clean/Minor wound	Contaminated/Major wound
<3 or ? doses	Toxoid	Toxoid + immunoglobulin
≥ 3 doses	Toxoid if >10yrs ago booster	Toxoid if >10yrs ago booster



- Prophylactic iv antibiotics not indicated
- Admit to burn center?
 - 10-40 yo: >3% total body surface area (TBSA) 3rd deg, >15% 2nd deg. [see below]
 - <10yo, >40yo: >10% 2nd or 3rd deg.
 - Burns to face, hands, feet, perineum, +/- joints
 - Circumferential extremity burns
 - Electrical burns

Burn wound assessment:

- Area:
 - Palm = 1% TBSA
 - Rule of 9s:
 - Head, arm, anterior leg, posterior leg = 9% each
 - Anterior + post. torso = 18% each
 - Kids: Head has greater TBSA%
- Depth: Can progress so initial assessment +/- accurate
 - 1st degree (superficial)
 - Epidermis; erythema; pain resolves 48-72hrs; no scar
 - 2nd degree (partial thickness)
 - Entire epidermis + variable dermis
 - Superficial: dermal appendages intact = heals ~3weeks, minimal-no scar
 - Deep: less pain than superficial, heals weeks-months, scarring → needs excision + graft
 - Painful (nerve endings exposed), red, edematous, blisters
 - 3rd degree (full thickness)
 - Full epidermis and dermis = no dermal appendages = no spontaneous regeneration
 - Can go deeper (4th degree → fascia, muscle, bone)
 - No pain (nerves fried), leathery/waxy/charred appearance, vessel thrombosis

Rule of 9's

