

# APPROACH TO THE PATIENT

## Preoperative Management of the Pheochromocytoma Patient

Karel Pacak

Section on Medical Neuroendocrinology, Reproductive and Adult Endocrinology Program, National Institute of Child Health and Human Development, National Institutes of Health, National Institutes of Health, Bethesda, Maryland 20892-1109

**Pheochromocytomas are rare neuroendocrine tumors with a highly variable clinical presentation, but they most commonly present as spells of headaches, sweating, palpitations, and hypertension. Patients with pheochromocytoma may develop complicated and potentially lethal cardiovascular and other complications, especially in the setting of diagnostic or interventional procedures (e.g. upon induction of anesthesia or during surgery). The serious and potentially lethal nature of such complications is due to the potent effect of paroxysmal release of catecholamines. Because this warrants prompt di-**

**agnosis and treatment, the physician should be aware of the clinical manifestations and complications of catecholamine excess and be able to provide proper preoperative management to minimize catecholamine-related pre-, intra-, and post-operative adverse events. The following clinical scenario and discussion aim to enhance the knowledge of the physician regarding the behavior of pheochromocytoma and to outline current approaches to comprehensive preoperative management of patients suffering from this tumor. (J Clin Endocrinol Metab 92: 4069–4079, 2007)**

### A Patient's Presentation

A 57-yr-old white male presented to the community hospital emergency room with a 3-wk history of presyncopal and syncopal episodes, as well as abdominal pain with intermittent nausea. The patient had reported brief feelings of light-headedness and fainting upon standing on three separate occasions before his admission. The third episode resulted in an injury to his head. At the emergency room, he also complained of abdominal pain associated with nausea.

In the past, other symptoms and problems included episodes of sweating lasting 1–2 min, palpitations, and dizziness (all three usually occurring once every 1–2 wk for the past 6 months), and blurred vision for the last 2–3 months. Past medical history was also significant for labile and difficult-to-control hypertension [treated with amlodipine (Norvasc) 10 mg and metoprolol (Toprol XL) 50 mg once a day] for the past 5 yr. He also had a history of severe weight gain (over 110 pounds) during the last 2 yr, compounded by low energy level. A few months before hospitalization, the patient was put on a diet and a weight loss medication (phentermine, 30 mg once a day for 2 months) resulting in a 70-pound weight loss; however, he continued to be hypertensive. In addition, he was previously diagnosed to have uncomplicated umbilical hernia, benign prostate hypertrophy, and bilateral knee osteoarthritis.

At the emergency room, in view of the recurrent episodes of syncope and recent history of abdominal pain associated with nausea, a work-up for cardio- and cerebrovascular events and a possible small bowel obstruction was initiated.

Abbreviations: CT, Computed tomography; ECG, electrocardiogram; EPI, epinephrine; MIBG, metaiodobenzylguanidine; NE, norepinephrine.

JCEM is published monthly by The Endocrine Society (<http://www.endo-society.org>), the foremost professional society serving the endocrine community.

Computed tomography (CT) of the abdomen revealed a 6.4-cm left adrenal gland mass, in addition to a small umbilical hernia with partial small bowel obstruction. Magnetic resonance imaging confirmed the diagnosis of the left adrenal mass that appeared heterogeneous with a bright signal on T2-weighted images. It also showed moderately distended loops of the small bowel. Electrocardiogram (ECG) did not show any ischemia.

The patient was taken to the operating room for urgent umbilical hernia repair. Upon induction of anesthesia, the patient developed a hypertensive crisis with a blood pressure of 250/150 mm Hg and tachycardia with a heart rate of 95 bpm. Therefore, surgery was immediately aborted. The patient was subsequently transferred to the intensive care unit, and an endocrinology consult was requested for suspicion of a possible pheochromocytoma. Biochemical evaluation for pheochromocytoma revealed elevated urine norepinephrine (NE) of 738  $\mu\text{g}/24\text{ h}$  (with an upper reference limit of 100  $\mu\text{g}/24\text{ h}$ ) and epinephrine (EPI) of 779  $\mu\text{g}/24\text{ h}$  (upper reference limit, 24  $\mu\text{g}/24\text{ h}$ ). Two days later, the patient underwent hernia repair with blood pressure and heart rate controlled by iv  $\alpha$ - and  $\beta$ -adrenoceptor blockade. The patient was discharged on phenoxybenzamine (Dibenzylamine), metoprolol, and amlodipine.

Subsequently, the patient was referred to the National Institutes of Health (NIH) for further evaluation of his left adrenal pheochromocytoma. The diagnosis of pheochromocytoma was confirmed, and the patient was put on preoperative  $\alpha$ - and  $\beta$ -adrenoceptor blockade. Three weeks before surgery, the patient was started on phenoxybenzamine 10 mg per day by mouth, which was gradually titrated up to 30 mg three times a day. He was also put on atenolol 25 mg/d by mouth, which was gradually titrated up to 50 mg twice a day and metyrosine (Demser) 250 mg three times a day. ECG revealed a first-degree AV block with QT interval of 464

msec. A transthoracic echocardiogram showed a mildly dilated left atrium and ventricle. Therefore, a cardiology consult was obtained; but no further recommendations were given. After the patient's blood pressure normalized, a liberal salt diet was recommended.

The day before the planned surgery, the patient was admitted to NIH Clinical Center. His average blood pressure and heart rate were 134/76 mm Hg and 65 bpm, respectively. At midnight, the patient was given an extra dose of 40 mg of phenoxybenzamine, 12.5 mg of atenolol, and 500 mg of metyrosine. Additionally, he received 1 liter of 5% dextrose with 0.45% normal saline. During the surgery the following morning, there was no significant change in blood pressure during tumor manipulation and removal. Postoperatively, the patient developed a few hours of lasting hypotension (average blood pressure of 83/49 mm Hg and heart rate of 87 bpm), which was treated with a dopamine drip. Histopathological examination confirmed the diagnosis of pheochromocytoma.

### Pheochromocytoma as Catecholamine Excess and Storm

The World Health Organization defines pheochromocytoma as a tumor arising from catecholamine-producing chromaffin cells in the adrenal medulla—an intraadrenal paraganglioma (1, 2). Closely related tumors of extraadrenal sympathetic (catecholamine producing) and parasympathetic (rarely catecholamine producing) paraganglia are classified as extraadrenal paragangliomas. For simplification, in this report, the term pheochromocytoma will be used to refer to both adrenal and sympathetic ganglia-derived extraadrenal tumors.

Practically all pheochromocytomas produce catecholamines with considerable variation in their content, depending on expression of biosynthetic enzymes as depicted in Fig. 1 (3–5). Most extraadrenal pheochromocytomas produce predominantly NE. Many adrenal tumors produce either NE and EPI, or few rarely produce predominantly EPI (e.g. in patients with multiple endocrine neoplasia type 2 and neurofibromatosis type 1). The concentrations of catecholamines in pheochromocytoma tissues are enormous (6), potentially creating a volcano that can erupt at any time. Significant eruptions result in a catecholamine storm called “attacks.” In addition, smaller and continuous eruptions usually result in various symptoms and signs that are characteristic of constant adrenoceptor overstimulation by catecholamines (Table 1). For example, in our series we found that in patients with sporadic NE-secreting pheochromocytomas, the average NE content was about 1,760,000 pg/g tissue with about 53% of its release each day. In sporadic EPI-secreting pheochromocytomas, the average EPI content was about 3,801,000 pg/g tissue, with about 5% of its release each day (Eisenhofer, G., unpublished observations). At such levels, any direct tumor stimulation may lead to abrupt and significant catecholamine release that exceeds normal plasma values 1000 times or more (7, 8). These differences in catecholamine content and release explain different clinical presentations and ultimately necessitate specific treatment for each patient.

However, in about 15–20% of patients with pheochromocytoma,

basal plasma or urine catecholamines are within normal limits (9, 10). Some of these cases may be explained by the presence of so-called “nonfunctional” or “silent” pheochromocytomas that do not secrete significant amounts of catecholamines. Nevertheless, most of these silent tumors synthesize and metabolize catecholamines to metanephrines (elevated either in plasma or urine) and show elevations in plasma catecholamines only during paroxysmal attacks possessing the same danger as other pheochromocytomas (11, 12). In addition to catecholamines, pheochromocytomas are known to produce other vasoactive substances (neuropeptide Y, adrenomedullin, and atrial natriuretic peptide) that may cause hypertension (9).

### Catecholamines and Adrenoceptors

The adrenoceptors are the final targets for catecholamines that are found in excess in most patients with pheochromocytoma (Fig. 1). Both EPI and NE have overlapping but different effects on  $\alpha$ - and  $\beta$ -adrenoceptors on various organs and systems (Table 2). In particular, EPI has a more potent effect on  $\beta_2$ -adrenoceptors than NE, whereas NE is a more potent  $\beta_1$ -adrenoceptor agonist than EPI. EPI is also a more potent  $\alpha$ -adrenoceptor agonist than NE. However, the proximity of sites of NE and EPI release to adrenoceptors and the resulting concentrations at effector sites are also important determinants of adrenoceptor-mediated responses to these two catecholamines (13, 14).

In patients with pheochromocytoma, both NE and EPI behave as hormones as they are released into circulation. As a circulating hormone, EPI (more than 95% derived from the adrenal medulla) acts potently on  $\beta_2$ -adrenergic receptors of the skeletal muscle vasculature causing vasodilation that results in hypotension (14–16). In contrast, NE released locally from sympathetic nerve endings within the vasculature causes  $\alpha_1$ -adrenoceptor-mediated vasoconstriction resulting in hypertension (14, 17). Both catecholamines, although NE to a higher degree, stimulate  $\beta_1$ -adrenoceptors resulting in an increased heart rate. Furthermore, EPI is important as a metabolic hormone (18). In particular, EPI stimulates lipolysis, ketogenesis, thermogenesis, and glycolysis, and raises plasma glucose levels by stimulating glycogenolysis and gluconeogenesis. EPI also has potent effects on pulmonary function, causing  $\beta_2$ -adrenoceptor-mediated dilation of airways. Thus, patients with EPI-secreting pheochromocytomas more frequently show episodic symptoms and signs with palpitations, light-headedness or syncope, anxiety, and hyperglycemia than patients with tumors that secrete mainly NE, who more often have continuous symptoms and signs including hypertension, sweating, and headache (3, 17, 19). These catecholamine-specific effects on adrenoceptors explain the wide range of clinical presentations of patients with pheochromocytomas and serve as the basis for appropriate preoperative adrenergic blockade. Although some patients need significant amounts of adrenoceptor blockers, some may not, despite high circulating catecholamine concentrations (often seen in patients with metastatic pheochromocytoma). This may be explained by so called “desensitization” that occurs by two mechanisms: internalization of receptors, reducing their number on the cell sur-

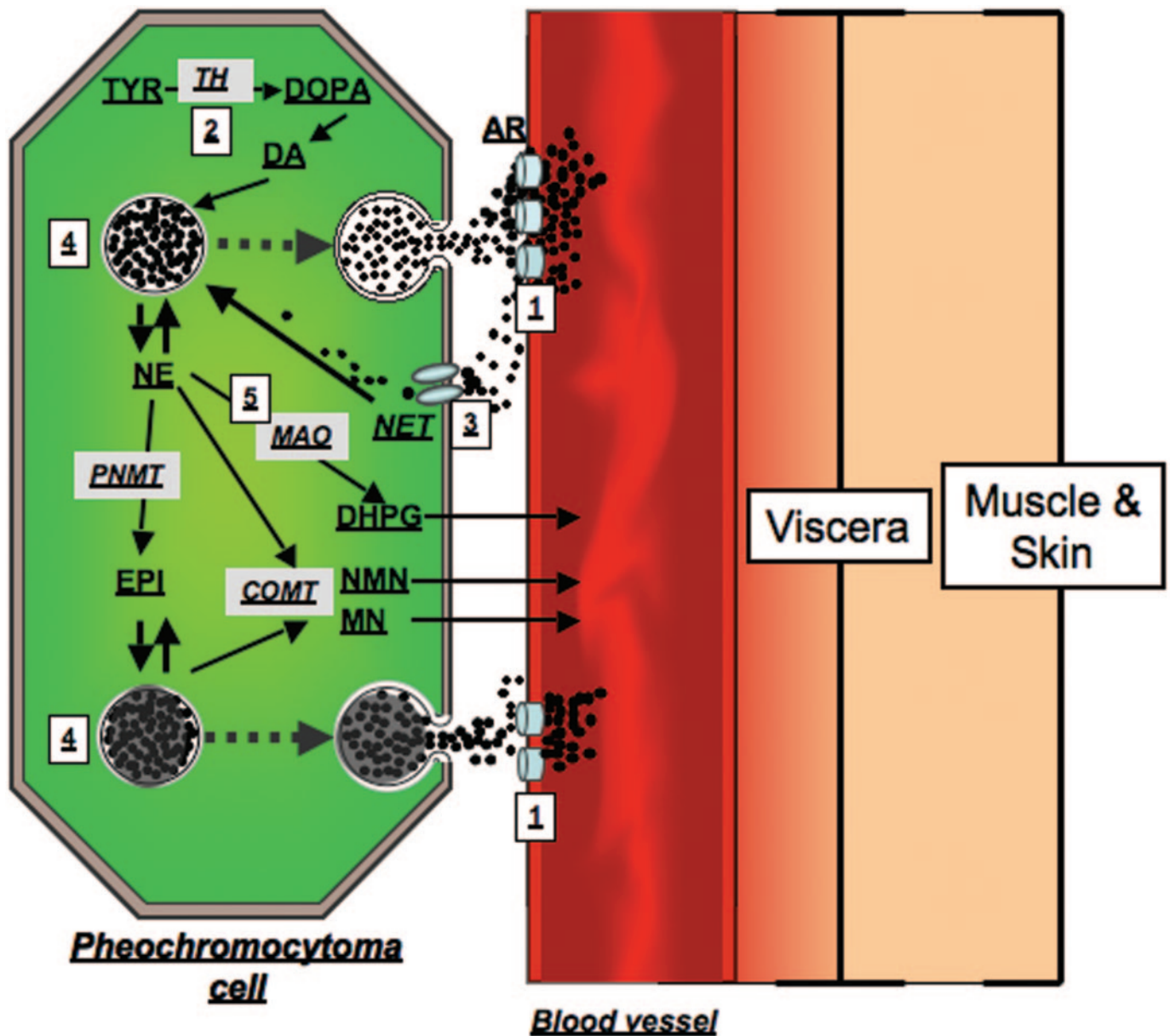


FIG. 1. Diagram illustrating the main pathways of catecholamine synthesis, release, and metabolism in pheochromocytoma. Numbers in squares indicate sites of: 1) action of  $\alpha$ - and  $\beta$ -adrenoceptor blockers or weight loss medications [phentermine (Adipex, Fastin, Zantryl), phendimetrazine (Bontril, Adipost, Plegine), methamphetamine (Desoxyn), and phenylethylamine (Fenphedra)] as sympathomimetic amines with a direct action on adrenoceptors; 2) Metyrosine (Demser) inhibition of TH; 3) inhibition of NE reuptake via NET (mainly on sympathetic nerve terminals) by the effect of tricyclic antidepressants [amitryptiline (Elavil, Endep), nortryptiline (Aventyl, Pamelor)], combined serotonin and NE reuptake inhibitors [duloxetine (Cymbalta), venlafaxine (Effexor)], sibutramine (Meridia), and cocaine; 4) where sympathomimetics (*e.g.* ephedrine, pseudoephedrine), and food containing tyramine (*e.g.* wine, cheese) release NE and EPI from storage vesicles; 5) MAO inhibitors [deprenyl (*Selegiline*)] blocking the conversion of NE to DHPG that results in accumulation and higher release of NE (mainly at sympathetic nerve terminals). TYR, Tyrosine; DOPA, dihydroxyphenylalanine; DA, dopamine; DHPG, dihydroxyphenylglycol; NMN, normetanephrine; MN, metanephrine; TH, tyrosine hydroxylase; PNMT, phenylethanolamine-N-methyltransferase; MAO, monoamine oxidase; COMT, catechol-O-methyltransferase; NET, norepinephrine cell membrane transporter; AR, adrenoceptors.

face; or decreased binding affinity of the catecholamine to the receptor (20, 21). This mechanism prevents, at least partially, a patient from the harmful effects of catecholamines, which often favor the administration of lower doses of adrenoceptor blockers and catecholamine synthesis inhibitors to minimize drug-related side effects.

### Current Views on Preoperative Blockade

The panel of experts at the First International Symposium on Pheochromocytoma recommended that all patients with a biochemically positive pheochromocytoma should receive appropriate preoperative medical management to block the

**TABLE 1.** Signs and symptoms in patients with pheochromocytoma

Signs		Symptoms	
Hypertension	++++	Headaches	++++
Sustained hypertension	++	Palpitations	++++
Paroxysmal hypertension	++	Anxiety/nervousness	+++
Postural hypotension	+	Tremulousness	++
Tachycardia or reflex bradycardia	+++	Weakness, fatigue	++
Excessive sweating	++++	Nausea/vomiting	+
Pallor	++	Pain in chest/abdomen	+
Flushing	+	Dizziness or faintness	+
Weight loss	+	Paresthesias	+
Fasting hyperglycemia	++	Constipation (rarely diarrhea)	+
Decreased gastrointestinal motility	+	Visual disturbances	+
Increased respiratory rate	+		

Frequency: highest (++++) to lowest (+). Adapted from Eisenhofer *et al.* (76).

effects of released catecholamines (2). Wide-ranging practices, international differences in available or approved therapies (22–29), and a scarcity of evidence-based studies comparing different therapies led to a lack of consensus regarding the recommended drugs for preoperative blockade. However,  $\alpha$ -adrenoceptor antagonists, calcium channel blockers, or angiotensin receptor blockers were all recommended. For tachyarrhythmias,  $\beta$ -adrenoceptor or calcium channel blockers were recommended, but it was emphasized that if  $\beta$ -adrenoceptor blockers are used, they should be used only after adequate pretreatment with  $\alpha$ -adrenoceptor antagonists to avoid hypertensive crisis from unopposed  $\alpha$ -adrenoceptor overstimulation (usually 2 d after  $\alpha$ -adrenoceptor blockers are given) (30). The mechanism for  $\beta$ -adrenoceptor blocker-associated adverse events is generally ascribed to inhibition of  $\beta_2$ -adrenoceptor-mediated vasodilatation, leaving  $\alpha$ -adrenoceptor-mediated vasoconstrictor responses to catecholamines unopposed (31).

The main goal of preoperative management of a pheochromocytoma patient is to normalize blood pressure, heart rate, and function of other organs; restore volume depletion; and prevent a patient from surgery-induced catecholamine storm and its consequences on the cardiovascular system. Therefore, when preoperative adrenergic blockade is started, drug doses are usually much higher, the combination of various drugs is often necessary, and targets for cardiovascular indices are much stricter than they would be if no operation was performed.

Currently, there is no consensus for when adrenergic blockade should be started when preparing a patient for surgery. In most medical centers, adrenergic blockade usually starts 7–14 d preoperatively to have adequate time to normalize blood pressure and heart rate and to expand the contracted blood volume (27, 32–36). In some patients who have organ damage from long-standing catecholamine excess (*e.g.* catecholamine-induced cardiomyopathy, vasculitis, recent myocardial infarction, and bowel movement dysfunction), adrenergic blockade can be initiated much earlier before the planned surgery. At our institution, our goal is to achieve preoperative blood pressure of 130/80 mm Hg or less while sitting and about 100 mm Hg systolic while standing (not less than 80/45 mm Hg) and target heart rate of about 60–70 bpm while sitting and 70–80 bpm while standing. At other institutions, the target blood pressure is either lower (37) or higher (9), depending on institutional experi-

ence. Nevertheless, recommendations regarding blood pressure and heart rate are supported by observational nonsystematic studies and personal experience rather than properly conducted prospective clinical studies.

#### $\alpha$ -Adrenoceptor antagonists

Phenoxybenzamine (Dibenzylamine; irreversible, noncompetitive,  $\alpha$ -adrenoceptor blocker) is most commonly used for preoperative blockade (Table 3). Phenoxybenzamine has a long-lasting effect that diminishes only after *de novo*  $\alpha$ -adrenoceptor synthesis. The initial dose of phenoxybenzamine is usually 10 mg twice a day and is increased until the clinical manifestations are controlled or side effects appear. Generally, a total daily dose of 1 mg/kg is sufficient. Some patients, however, may require much larger doses that, at our institution, are usually increased in increments of 10 to 20 mg every 2 to 3 d. If the initial dosage is too high, the patient will have significant postural hypotension with reflex tachycardia, dizziness, syncope, nasal congestion, and other side effects, and dose titration is warranted. As the correct dose is approached, paroxysmal hypertensive episodes are brought under control, and when the right dose is achieved the patient becomes normotensive or mildly hypotensive. Additionally, the prolonged action of phenoxybenzamine can contribute to hypotension in the first 24 h after tumor removal (38). Another option is to administer phenoxybenzamine by infusion (0.5 mg/kg·d) for 5 h a day, 3 d before the operation (39, 40). This approach, however, requires that the patient be admitted to the hospital and closely monitored; this period is usually too short to start catecholamine synthesis inhibitors to achieve maximum effect as discussed below. Two studies reported no correlation between duration of treatment (less than 1 wk *vs.* a longer time period) with phenoxybenzamine and cardiovascular intraoperative stability (41, 42). Furthermore, it should be mentioned that compared with  $\alpha_1$ -adrenoceptor blockers, phenoxybenzamine is an expensive drug; therefore, it is mainly limited to patients with appropriate health insurance.

Other  $\alpha$ -adrenoceptor blocking agents of use are prazosin (Minipress), terazosin (Hytrin), and doxazosin (Cardura) (Table 3) (43, 44). All three are specific, competitive, and therefore short-acting  $\alpha_1$ -adrenergic antagonists. Prazosin is administered in doses of 2 to 5 mg two or three times a day, terazosin is given in doses of 2 to 5 mg per day, and dox-

**TABLE 2.** Adrenoceptor-mediated responses of effector organs

Effector organs	Receptor type	Responses	Most relevant clinical manifestations
Eye			
Radial muscle, iris	$\alpha_1$	Contraction (mydriasis) ++	Blurry vision
Ciliary muscle	$\beta_2$	Relaxation for far vision +	
Heart			
SA node	$\beta_1, \beta_2$	Increase in heart rate ++	Palpitations, angina
Atria	$\beta_1, \beta_2$	Increase in contractility and conduction velocity ++	
AV node	$\beta_1, \beta_2$	Increase in automaticity and conduction velocity +++	
His-Purkinje system	$\beta_1, \beta_2$	Increase in automaticity and conduction velocity +++	
Ventricles	$\beta_1, \beta_2$	Increase in contractility, conduction velocity, automaticity, and rate of idioventricular pacemakers +++	
Arterioles			
Coronary	$\alpha_1, \alpha_2; \beta_2$	Constriction +; dilations ++	Angina
Skin and mucosa	$\alpha_1, \alpha_2$	Constriction +++	Pallor
Skeletal muscle	$\alpha; \beta_2$	Constriction ++; dilations ++	Hypertension
Cerebral	$\alpha_1$	Constriction (slight)	Stroke
Pulmonary	$\alpha_1; \beta_2$	Constriction +; dilations ++	Edema
Abdominal viscera	$\alpha_1; \beta_2$	Constriction +++; dilations +	<i>E.g.</i> Bowel ischemia
Salivary glands	$\alpha_1, \alpha_2$	Constriction +++	
Renal	$\alpha_1, \alpha_2; \beta_1, \beta_2$	Constriction +++; dilations +	Renal failure
Veins (systemic)	$\alpha_1, \alpha_2; \beta_2$	Constriction ++; dilations ++	Orthostatic hypotension
Lung			
Tracheal and bronchial muscle	$\beta_2$	Relaxation +	
Bronchial glands	$\alpha_1; \beta_2$	Decreased secretion; increased secretion	
Stomach			
Motility and tone	$\alpha_1, \alpha_2; \beta_2$	Decrease (usually) +	Early satiety, discomfort
Sphincters	$\alpha_1$	Contraction (usually) +	
Intestine			
Motility and tone	$\alpha_1, \alpha_2; \beta_1, \beta_2$	Decrease +	Constipation, ileus
Sphincters	$\alpha_1$	Contraction (usually) +	
Secretion	$\alpha_2$	Inhibition	Constipation
Gallbladder and ducts	$\beta_2$	Relaxation +	Gallstones
Kidney			
Renin secretion	$\alpha_1; \beta_2$	Decrease +; increase ++	
Urinary bladder			
Detrusor	$\beta_2$	Relaxation (usually) +	Urinary retention
Trigone and sphincter	$\alpha_1$	Contraction ++	Urinary retention
Ureter			
Motility and tone	$\alpha_1$	Increase	
Uterus	$\alpha_1; \beta_2$	Pregnant: contraction; relaxation Nonpregnant: relaxation	
Sex organs, male	$\alpha_1$	Ejaculation ++	
Skin			
Pilomotor muscles	$\alpha_1$	Contraction ++	
Sweat glands	$\alpha_1$	Localized secretion +	Sweating
Spleen capsule	$\alpha_1; \beta_2$	Contraction +++; relaxation +	
Skeletal muscle	$\beta_2$	Increased contractility; glycogenolysis; $K^+$ uptake	Hyperglycemia, glycosuria
Pancreas			
Acini	$\alpha$	Decreased secretion +	
Islets ( $\beta$ cells)	$\alpha_2$	Decreased secretion +++	Hyperglycemia, glycosuria
	$\beta_2$	Increased secretion +	Hypoglycemia
Fat cells	$\alpha_2; \beta_1, \beta_2$	Lipolysis +++ (thermogenesis)	Feeling warm
Salivary glands	$\alpha_1$	$K^+$ and water secretion +	
	$\beta$	Amylase secretion +	
Lacrimal glands	$\alpha$	Secretion +	Lacrimation
Pineal gland	$\beta$	Melatonin synthesis	
Posterior pituitary	$\beta_1$	Antidiuretic hormone secretion	Decreased diuresis

Highest (+++) to lowest (+) intensity of adrenergic nerve activity in the control of various organs and functions listed. Where (+) is not given, intensity is not specified. SA, Sinoatrial; AV, atrioventricular. Adapted from Pacak *et al.* (86).

azosin in doses of 2 to 8 mg per day. However, all three have the potential for severe postural hypotension immediately after the first dose; thus, they should be given just as the patient is ready to go to bed. Thereafter, the dosage can be increased as needed; titration can be achieved more quickly with much less side effects (no reflex tachycardia, less postoperative hypotension) compared with phenoxybenzamine. In patients with EPI-secreting tumors, the absence of reflex

tachycardia (due to no effect on presynaptic  $\alpha_2$ -adrenoceptors, which if inhibited increase NE release) can be advantageous in patients who also have coronary artery disease. In volume-depleted patients,  $\alpha_1$ -adrenergic antagonists must be used cautiously because hypotensive effects may be more significant. Although some studies suggest that these drugs can control blood pressure pre-, intra-, and postoperatively as effectively as phenoxybenzamine, other studies do not

support such conclusions (25, 45, 46). Because of a short half-life of  $\alpha_1$ -adrenergic antagonists, these drugs should also be given in the morning before surgery. In some institutions, phenoxybenzamine is used first and then replaced by  $\alpha_1$ -adrenergic antagonists before surgery to reduce postoperative hypotension (37).

In summary,  $\alpha$ -adrenoceptor blockade has a significant impact on surgical outcome as demonstrated in the study of Goldstein *et al.* (47) where 69% of patients without  $\alpha$ -adrenoceptor blockade experienced perioperative complications compared with only 3% with blockade. Experience at our and other institutions along with current pheochromocytoma expert views confirm these conclusions and results (2, 48–50), whereas previously published data suggested that preoperative  $\alpha$ -adrenoceptor blockade may not be necessary (51). Thus, currently it depends on institutional preference whether to use  $\alpha$ - or specific  $\alpha_1$ -adrenergic antagonists because they both are well accepted in the preoperative management of a pheochromocytoma patient. Regardless of which  $\alpha$ -adrenoceptor antagonist and its dose are used, no complete  $\alpha$ -adrenoceptor can be achieved as presented by a number of patients with intraoperative hypertension and tachyarrhythmia (38, 41, 52).

#### $\beta$ -Adrenoceptor antagonists

$\beta$ -Adrenoceptor blocking agents are needed when catecholamine- or  $\alpha$ -blocker-induced tachyarrhythmia occurs (Table 3). A  $\beta$ -adrenoceptor blocker should never be used in the absence of an  $\alpha$ -adrenoceptor blocker because the former will exacerbate EPI-induced vasoconstriction by blocking its vasodilator component. This will make hypertensive episodes worse in subjects who are on a  $\beta$ -adrenoceptor blocker alone. Currently, cardioselective  $\beta_1$ -adrenoceptor blockers are preferable (Table 3). Atenolol (Tenormin) is administered in doses of 12.5 to 25 mg two or three times a day, and metoprolol (Lopressor) in doses 25–50 mg three to four times a day (Toprol XL in doses 25–200 mg once a day). Propranolol (Inderal) as a nonselective  $\beta$ -adrenoceptor blocker is also used and is given in doses of 20 to 80 mg one to three times a day.

#### Combined $\alpha$ - and $\beta$ -adrenoceptor antagonists

Although labetalol (Normodyne or Trandate), a drug with both  $\alpha$ - and  $\beta$ -antagonistic activity, has been used for preoperative adrenoceptor blockade, it should not be used as the primary choice for blockade (53–55). With labetalol, one is forced to use a fixed ratio of  $\alpha$ - to  $\beta$ -antagonistic activity that is about 1:7 (if given orally) (56), which may result in paradoxical episodes of hypertension or even hypertensive crisis (57). Note that the  $\alpha$ - to  $\beta$ -antagonistic activity should be at least 4:1 to achieve adequate antihypertensive effect (58). Carvedilol (Coreg) is another new antihypertensive drug with similar effects as labetalol. Thus, these drugs are not recommended for preoperative adrenoceptor blockade, except in the situation when a patient is on  $\alpha$ - and  $\beta$ -adrenoceptor blockers that need to be replaced (*e.g.* due to side effects). Moreover, labetalol significantly reduces the uptake of  $^{131}\text{I}$ -metaiodobenzylguanidine (MIBG) and needs to be stopped about 2 wk before  $^{131}\text{I}$ -MIBG scintigraphy (59).

#### Calcium channel blockers

Perhaps less effective than  $\alpha$ -adrenoceptor blockers, calcium channel blockers provide another option for preparing the patient preoperatively (22, 26, 60, 61). These drugs block NE-mediated calcium influx into vascular smooth muscle, thereby controlling hypertension and tachyarrhythmias. It is the view of the author and others that currently, there are three main roles of these drugs in pheochromocytoma patients (9, 37): 1) to supplement adrenoceptor blockers in patients with inadequate blood pressure control, obviating the need to increase the dosage of  $\alpha$ -adrenoceptor blockers; 2) to replace adrenoceptor blockers in patients with severe side effects; and 3) to prevent adrenoceptor blocker-induced sustained hypotension in patients with only intermittent hypertension. Calcium channel blockers do not cause hypotension or orthostatic hypotension during normotensive period (62). These agents may also prevent catecholamine-associated coronary spasm; therefore, they may be useful when pheochromocytoma is associated with catecholamine-induced coronary vasospasm. In some medical institutions, calcium channel blockers are the primary preoperative treatment of choice in normotensive patients with pheochromo-

**TABLE 3.** Main classes of drugs with contraindications in patients with pheochromocytoma

Drug class	Relevant clinical uses
$\beta$ -Adrenergic blockers <sup>a</sup>	May be used to treat conditions that result from catecholamine excess ( <i>e.g.</i> hypertension, cardiomyopathy, heart failure, panic attacks, migraine, tachycardia and cardiac dysrhythmias)
Dopamine D2 receptor antagonists	Control of nausea, vomiting, psychosis, hot flashes and for tranquilizing effect
Tricyclic antidepressants	Treatment of insomnia, neuropathic pain, nocturnal enuresis in children, headaches, depression (rarely)
Other antidepressants (serotonin and NE reuptake inhibitors)	Depression, anxiety, panic attacks, antiobesity agents
Monoamine oxidase inhibitors	Non-selective agents rarely used as antidepressants (due to "cheese effect").
Sympathomimetics <sup>a</sup>	Control of low blood pressure during surgical anesthesia; decongestants; antiobesity agents
Chemotherapeutic agents <sup>a</sup>	Antineoplastic actions; treatment of malignant pheochromocytoma
Opiate analgesics <sup>a</sup>	Induction of surgical anesthesia
Neuromuscular blocking agents <sup>a</sup>	Induction of surgical anesthesia
Peptide and steroid hormones <sup>a</sup>	Diagnostic testing

Adapted from Eisenhofer *et al.* (76).

<sup>a</sup> These drugs have therapeutic or diagnostic use in pheochromocytoma, but usually only after pretreatment with appropriate antihypertensives (*e.g.*  $\alpha$ -adrenoceptor blockers).

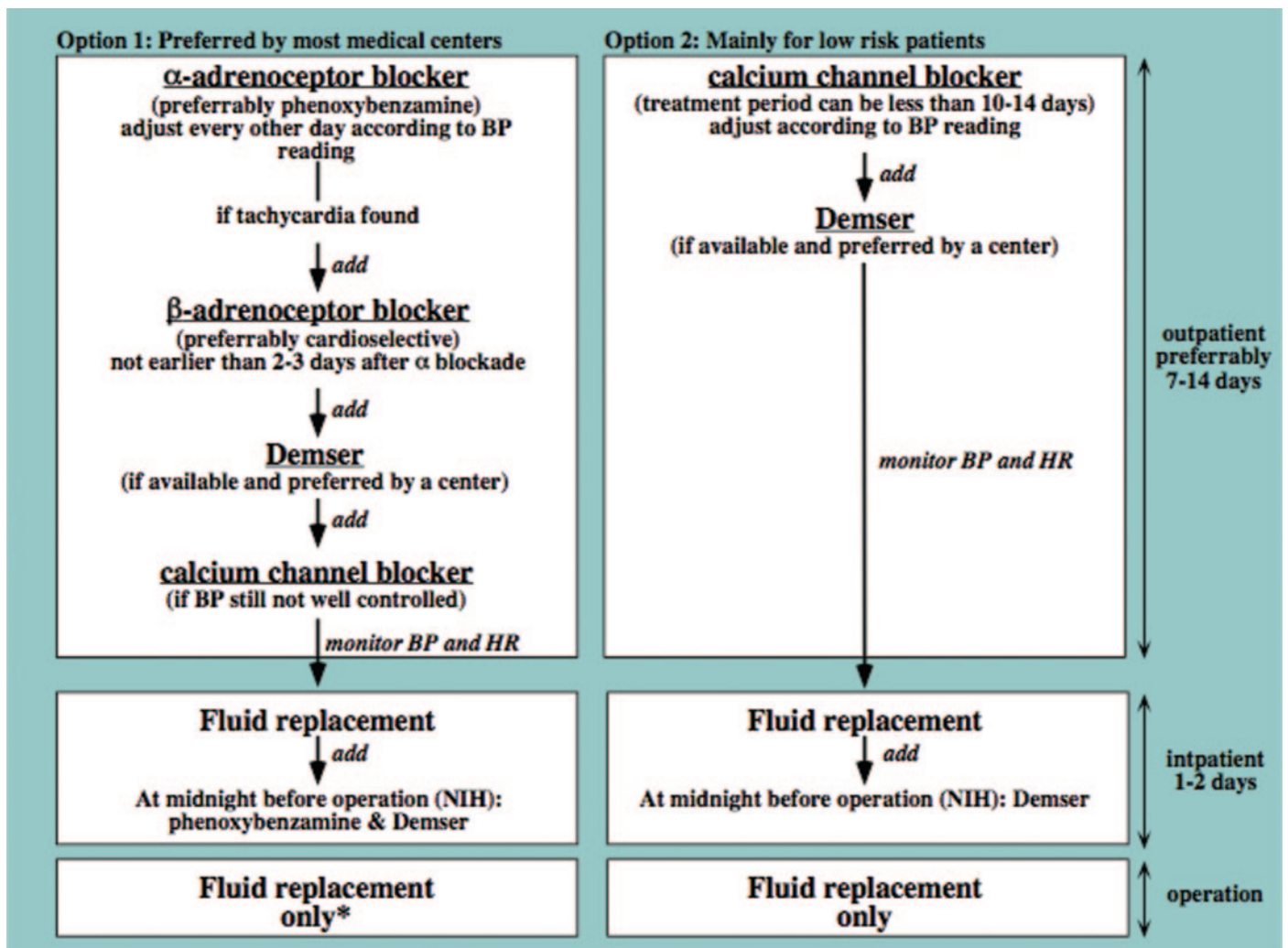


FIG. 2. Current recommended preoperative treatment algorithms in patients with pheochromocytoma. BP, Blood pressure; HR, heart rate. \*, If  $\alpha_1$ -adrenoceptor blockers are used, then give one dose in the morning before surgery.

cytoma (51). Amlodipine (Norvasc) is given in a dose from 10–20 mg, and nifedipine (Cardene) in a dose from 60–90 mg per day. Nifedipine (Adalat) is given in a dose from 30–90 mg and verapamil (Covera-HS, Calan-SR) in a dose from 180–540 mg per day. Both nifedipine and verapamil have extended-release action.

### Catecholamine Synthesis Inhibition

A good correlation exists between the perioperative cardiovascular instability and catecholamine release (41). Therefore, the administration of drugs that block catecholamine synthesis, thereby decreasing the stimulation of various adrenoceptors by lowering circulating catecholamine levels, is an important component of preoperative management.  $\alpha$ -Methyl-L-tyrosine or metyrosine (Demser) is an analog of tyrosine that competitively inhibits tyrosine hydroxylase, the rate-limiting step in catecholamine biosynthesis (63). It significantly but not completely depletes catecholamine stores with maximum effect after about 3 d of treatment (Fig. 1) (64). The drug is usually used to control high blood pressure in

patients with pheochromocytoma, particularly those with extensive metastatic disease or preoperatively in patients with biochemically active tumors (65–68). It is preferably used together with other adrenergic blockers due to incomplete depletion of catecholamine stores regardless of the dose used (27, 37, 67, 69). Despite the well-documented effect of metyrosine on catecholamine synthesis, this treatment has been adopted by only a few institutions (37, 66, 69). This is partially due to the limited availability of this drug and its side effects evident at high doses.

Metyrosine facilitates blood pressure control both before and during surgery, especially during the induction of anesthesia and surgical manipulation of the tumor when extensive sympathetic activation or catecholamine release occurs (66, 67). At our institution, treatment is started in all surgical candidates at a dose of 250 mg orally every 8 to 12 h and, thereafter, the dose is increased by 250 to 500 mg every 2 to 3 d or as necessary up to a total dose of 1.5 to 2.0 g per day. We treat for 1–3 wk before surgery depending on blood pressure and heart rate normalization. The drug, a substi-

ALPHA AR		BETA AR	
Alpha <sub>1</sub>	Alpha <sub>2</sub>	Beta <sub>1</sub>	Beta <sub>2</sub>
<b>Antagonists used in pheochromocytoma</b>			
Prazosin, Doxazosin, Terazosin		Atenolol	
Phenoxybenzamine, Phentolamine		Metoprolol	
Labetalol Carvedilol		Propranolol, Timolol, Nadolol, Penbutolol, Sotalol	
		Labetalol	

FIG. 3. PLEASE SUPPLY COPY

tuted amino acid, called  $\alpha$ -methyl-L-tyrosine, readily crosses the blood–brain barrier. Thus, it inhibits catecholamine synthesis in the brain as well as in the periphery, frequently causing sedation (often sleepiness), depression, anxiety, and galactorrhea, and rarely causes extrapyramidal signs (*e.g.* parkinsonism in elderly patients) (27, 37). If these side effects do not resolve quickly when the dosage is lowered, the drug should be discontinued. Metyrosine also causes diarrhea and crystalluria, especially when doses are higher than 4 g per day, although such a dose is rarely used. Metyrosine and  $\alpha$ -adrenoceptor blockers when used together result in less labile blood pressure during anesthesia and surgery (but elevated blood pressure still occurs in up to 30–80% of patients), reduced intraoperative blood loss, and reduced volume replacement during surgery compared with the use of  $\alpha$ -adrenoceptor blockers alone (66, 67, and 70; and author's personal observations).

In summary, although large randomized, prospective, and controlled studies are lacking, data from retrospective studies suggest that  $\alpha$ -adrenoceptor blockade is currently the preferred choice in preoperative management of hypertensive pheochromocytoma patients to improve surgical outcome (Fig. 2) (28, 37, 47, 71). Calcium channel blockers and  $\beta$ -adrenoceptor blockers (72) are most often used as co-drugs when blood pressure cannot be well controlled while on  $\alpha$ -adrenoceptor blockade or if tachyarrhythmia occurs. At some medical institutions metyrosine is given to all patients, and at others only to those patients who have highly active tumors associated with difficult-to-treat symptoms and signs of catecholamine excess.

Normotensive patients (in some series up to 30–40% so called low-risk patients) often become hypertensive during surgery, and demonstrate the unpredictable nature of blood pressure changes during an operation (34, 73–75). Thus, normotensive patients should also be given  $\alpha$ -adrenoceptor or calcium channel blockers preoperatively. Exceptions where

treatment may not be required for blood pressure and heart rate control include patients with parasympathetic-derived head and neck paragangliomas that do not produce catecholamines or patients with very rare tumors producing only dopamine (5, 36).

### Drugs with Interfering Effects on Catecholamine Turnover

The administration of drugs that provoke the release of catecholamines produced by the tumor or interfere with catecholamine turnover may have devastating, even lethal consequences (Fig. 1 and Table 3) (76). NE and EPI release can be provoked by glucagon, steroids, histamine, angiotensin II, and vasopressin. Displacement of catecholamines from storage vesicles by sympathomimetic amines (*e.g.* tyramine in cheese, bananas, wine, soy sauce, avocados, and any fermented, smoked, or aged meat and fish), followed by their release into circulation provides another example of how pheochromocytomas may be pharmacologically provoked (77). Of the drugs used for obesity management, phentermine (Adipex, Fastin, and Zantryl), phendimetrazine (Bontril, Adipost, and Plegine), methamphetamine (Desoxyn), and phenylethylamine (Fenphedra) are sympathomimetic amines with a direct action on adrenoceptors. Over-the-counter use of nasal decongestants, such as formulations containing ephedrine, pseudoephedrine, or phenylpropanolamine, and currently some weight loss medications provide the most common source of drug interference. Drugs that decrease NE reuptake [*e.g.* tricyclic and other antidepressants: amitriptyline (Elavil, Endep), nortriptyline (Aventyl, Pamelor), edronax (Reboxetine), duloxetine (Cymbalta), venlafaxine (Effexor); cocaine; weight loss medication sibutramine (Meridia); and those that influence NE metabolism, *e.g.* monoamine oxidase inhibitors: deprenyl (Selegiline)] contribute significantly to high circulating NE levels (mainly derived from sympathetic nerve terminals). NE reuptake inhibitors can interfere with the biochemical and imaging studies by two mechanisms: 1) blocking tumor cell uptake of <sup>123</sup>I- and <sup>131</sup>I-MIBG and other imaging agents (<sup>18</sup>F-fluorodopamine) that use the NE transporter; and 2) blocking reuptake of NE by neuronal cell membrane NE transporter, thereby leading to false-positive elevations of plasma NE and downstream metabolites (metanephrines) (78). Regardless of tumor presence, they may increase catecholamine levels and increase the propensity for a hypertensive crisis. NE metabolism modulators such as monoamine oxidase inhibitors block the conversion of metanephrines to methoxyhydroxyphenylglycol, leading to false-positive elevations in plasma and urinary metanephrines (13). Furthermore, these inhibitors allow tyramine from the diet to escape into the systemic circulation where it promotes NE release from sympathetic nerves (cheese effect) in normal people and catecholamine release by tumors in patients with pheochromocytoma. Linezolid (Zyvox), a novel oxazolidinone antibiotic, has monoamine oxidase inhibitory properties; thus, caution is warranted in pheochromocytoma patients. Dopamine receptor antagonists, such as metoclopramide (Reglan), chlorpromazine (Thorazine), and prochlorperazine (Compazine), used



as antipsychotic and antiemetic drugs, can also provoke catecholamine release from pheochromocytoma.

### Cardiovascular Evaluation, Blood Volume Restoration, and Other Recommendations

A detailed history, physical examination, and a complete laboratory and cardiac evaluation are essential in preparation of the patient with pheochromocytoma for surgery. An accurate preoperative cardiovascular examination should be carried out, especially to detect the presence of a cardiomyopathy or coronary artery disease. In younger, otherwise healthy patients, preoperative ECG is usually sufficient. In some cases, echocardiography can be helpful to delineate the degree of cardiac compromise, especially in patients with long-standing hypertension. The value of preoperative echocardiography in patients without cardiac symptoms or clinical evidence of cardiac involvement has been questioned (79). Assessment of reduced myocardial contractility using Doppler echocardiography appears to predict risk of perioperative collapse better than conventional echocardiography (80). Cardiovascular function is optimized by relaxation of the constricted vasculature, expansion of the reduced plasma volume, and normalization of blood pressure for 1 to 2 wk before surgery.

Normalization of blood volume minimizes the possibility of protracted hypotension or shock resulting from sudden diffuse vasodilation at the time of tumor removal. If the blood pressure is controlled and the patient is given a normal or high-salt diet (usually 3 d after  $\alpha$ -adrenoceptor blocker is given), the patient's diminished blood volume is typically restored to normal, and the degree of postural hypotension decreases. However, the treatment with  $\alpha$ -adrenoceptor blockers alone will result in blood volume restoration in only about 60% of patients (81). If catecholamine-induced hyperglycemia is found preoperatively, close monitoring should be initiated, and occasionally treatment may be necessary if hyperglycemia is severe.

In patients with a large left adrenal pheochromocytoma, splenectomy is likely; therefore, vaccination against pneumococcus, *Haemophilus influenzae*, and meningococcus should be given preoperatively.

Strenuous physical activity should be limited, and smoking and alcohol consumption should be avoided because they all significantly increase catecholamine release from a tumor.

### Hospital Admission

In most medical centers, the patient is admitted the day before surgery. At our institution, we administer phenoxybenzamine and metyrosine (usually 0.25–1 mg/kg and 500 mg orally, respectively) at midnight before surgery. The patient is instructed to stay in bed, with the rails raised to prevent a fall from hypotension. To avoid further significant hypotension after the tumor is removed, no morning doses are given. The continuous administration of saline (usually 1–2 liters) starting the evening before surgery results in further expansion of intravascular volume and reduction of frequency and severity of postoperative hypotension (Fig. 2). Occasionally, sodium nitroprusside (Nipride) and labetalol

or phentolamine (Regitine) infusion can be used preoperatively in patients with drug-resistant hypertension or hypertensive crisis, respectively (37). Sodium nitroprusside and phentolamine have a rapid onset of action but also end of effect. All these drugs are given to patients upon admission to the intensive care unit.

### Special Considerations

Often preoperative management includes CT imaging to either reassess tumor location and its growth or to rule out metastatic disease. Although, it is a common belief that contrast media used for CT scans can induce hypertensive crisis in patients with pheochromocytoma, previous studies and our observations (which included 17 pheochromocytoma patients and six control subjects) do not support such a conclusion (82, 83). Nonionic CT contrast does not have any appreciable effect on NE and EPI release in various types of pheochromocytoma patients; therefore, adrenoceptor blockade does not seem to be necessary as a specific precautionary measure before iv nonionic contrast.

For pediatric patients, there are no other special considerations except when metyrosine is administered. Parents must be given clear instructions to report to a physician immediately if their child develops symptoms of depression and anxiety after taking metyrosine (84).

In pregnant patients, none of the  $\alpha$ - and  $\beta$ -adrenoceptor blockers have been associated with any problem except propranolol, which, anecdotally, was reported to be associated with intrauterine growth retardation, fetal bradycardia, and hypoglycemia as well as premature labor (85). Timing of surgery and delivery should be decided through a close discussion and work among obstetricians, endocrinologists, anesthesiologists, and surgeons (36).

### Back to the Patient

This case clearly illustrates the need for the use of proper preoperative adrenoceptor blockade and other important preventive measures in pheochromocytoma patients. All such measurements are essential not only before a planned operation, but also before any procedures (e.g. biopsy, endoscopy, radiofrequency ablation) that are expected to be associated with excessive catecholamine release from the tumor. Regarding our patient, several teaching points are of value. Typical symptoms and signs suggestive of catecholamines excess (e.g. recurrent short episodes of sweating and palpitations), together with difficult-to-treat hypertension should arouse immediate suspicion of pheochromocytoma. The findings of a mass with bright signal on a magnetic resonance imaging T2-weighted image together with typical symptoms and signs of catecholamine excess almost invariably confirm the presence of pheochromocytoma. However, the possibility of drug-induced elevation of catecholamine levels with symptoms and signs similar to pheochromocytoma should be ruled out before the final diagnosis is established. The patient presented here was on phentermine, which most likely contributed to his cardiovascular problems. The biochemical confirmation of the presence of pheochromocytoma should be based on measurements of metanephrines in plasma or urine.  $\alpha$ -Adrenergic blockers should

be used for preoperative preparation of a patient.  $\beta$ -Adrenergic blockers should be used if tachyarrhythmia is present and only after  $\alpha$ -adrenergic blockers have been administered. Calcium channel blockers seem to be a useful alternative in low-risk patients.

Furthermore, to ensure ideal preoperative preparation of patients with pheochromocytoma, very close communication between the endocrine, surgical, medical, cardiology, pediatric, oncology, radiology, and anesthesia teams is essential. Such teamwork should be directed to meet the three most essential goals: treat hypertension and tachyarrhythmias, restore the vascular volume, and treat any tumor or catecholamine excess-associated medical problems. With all these current recommendations in place, the Hippocrates phrase “To do good or to do no harm” reflects a physician’s best effort toward a pheochromocytoma patient before surgery.

### Acknowledgments

The author appreciates the technical assistance and valuable comments of the following members of the Pheochromocytoma Research Program: K. Adams, G. Eisenhofer, K. Horak, E. Lai, D. Makey, S. Perera, and D. Solis.

Received August 1, 2007. Accepted September 18, 2007.

Address all correspondence and requests for reprints to: Karel Pacak, M.D., Ph.D., D.Sc., Professor of Medicine, Chief, Section on Medical Neuroendocrinology, National Institute of Child Health and Human Development, National Institutes of Health, Building 10, CRC, Room 1E-3140, 10 Center Drive MSC-1109, Bethesda, Maryland 20892-1109. E-mail: karel@mail.nih.gov.

The writing of this article was supported by the intramural program of the National Institute of Child Health and Human Development, at the National Institutes of Health (Bethesda, Maryland).

The author has nothing to disclose.

### References

- DeLellis RA, Lloyd RV, Heitz PU, Eng C 2004 Tumours of endocrine organs. Lyon: IARC Press
- Pacak K, Eisenhofer G, Ahlman H, Bornstein SR, Gimenez-Roqueplo AP, Grossman AB, Kimura N, Mannelli M, McNicol AM, Tischler AS 2007 Pheochromocytoma: recommendations for clinical practice from the First International Symposium. *Nat Clin Pract Endocrinol Metab* 3:92–102
- Eisenhofer G, Walther MM, Huynh TT, Li ST, Bornstein SR, Vortmeyer A, Mannelli M, Goldstein DS, Linehan WM, Lenders JW, Pacak K 2001 Pheochromocytomas in von Hippel-Lindau syndrome and multiple endocrine neoplasia type 2 display distinct biochemical and clinical phenotypes. *J Clin Endocrinol Metab* 86:1999–2008
- Eisenhofer G, Lenders J, Linehan W, Walther M, Goldstein D, Keiser H 1999 Plasma normetanephrine and metanephrine for detecting pheochromocytoma in von Hippel-Lindau disease and multiple endocrine neoplasia type 2. *N Engl J Med* 340:1872–1879
- Eisenhofer G, Goldstein DS, Sullivan P, Csako G, Brouwers FM, Lai EW, Adams KT, Pacak K 2005 Biochemical and clinical manifestations of dopamine-producing paragangliomas: utility of plasma methoxytyramine. *J Clin Endocrinol Metab* 90:2068–2075
- Huynh TT, Pacak K, Brouwers FM, Abu-Asab MS, Worrell RA, Walther MM, Elkahoul AG, Goldstein DS, Cleary S, Eisenhofer G 2005 Different expression of catecholamine transporters in pheochromocytomas from patients with von Hippel-Lindau syndrome and multiple endocrine neoplasia type 2. *Eur J Endocrinol* 153:551–563
- Schuttler J, Westhofen P, Kania U, Ihmsen H, Kammerecker S, Hirner A 1995 Quantitative assessment of catecholamine secretion as a rational principle of anesthesia management in pheochromocytoma surgery. *Anesthesiol Intensivmed Notfallmed Schmerzther* 30:341–349
- Pacak K, Fojo T, Goldstein DS, Eisenhofer G, Walther MM, Linehan WM, Bacheneimer L, Abraham J, Wood BJ 2001 Radiofrequency ablation: a novel approach for treatment of metastatic pheochromocytoma. *J Natl Cancer Inst* 93:648–649
- Bravo E 1994 Evolving concepts in the pathophysiology, diagnosis, and treatment of pheochromocytoma. *Endocr Rev* 15:356–368
- Shawar L, Svec F 1996 Pheochromocytoma with elevated metanephrines as the only biochemical finding. *J La State Med Soc* 148:535–538
- Eisenhofer G, Keiser H, Friberg P, Mezey E, Huynh TT, Hiremagalur B, Ellingson T, Duddempudi S, Eijsbouts A, Lenders JW 1998 Plasma metanephrines are markers of pheochromocytoma produced by catechol-O-methyltransferase within tumors. *J Clin Endocrinol Metab* 83:2175–2185
- Shen SJ, Cheng HM, Chiu AW, Chou CW, Chen JY 2005 Perioperative hypertensive crisis in clinically silent pheochromocytomas: report of four cases. *Chang Gung Med J* 28:44–50
- Eisenhofer G, Kopin IJ, Goldstein DS 2004 Catecholamine metabolism: a contemporary view with implications for physiology and medicine. *Pharmacol Rev* 56:331–349
- Ito Y, Fujimoto Y, Obara T 1992 The role of epinephrine, norepinephrine, and dopamine in blood pressure disturbances in patients with pheochromocytoma. *World J Surg* 16:759–763
- Eisenhofer G, Rundqvist B, Aneman A, Friberg P, Dakak N, Kopin IJ, Jacobs MC, Lenders JW 1995 Regional release and removal of catecholamines and extraneuronal metabolism to metanephrines. *J Clin Endocrinol Metab* 80:3009–3017
- Eisenhofer G, Friberg P, Pacak K, Goldstein DS, Murphy DL, Tsigos C, Quyyumi AA, Brunner HG, Lenders JW 1995 Plasma metadrenalines: do they provide useful information about sympatho-adrenal function and catecholamine metabolism? *Clin Sci* 88:533–542
- Bravo EL, Tarazi RC, Fouad FM, Textor SC, Gifford Jr RW, Vidt DG 1982 Blood pressure regulation in pheochromocytoma. *Hypertension* 4:193–199
- Cryer PE 1993 Adrenaline: a physiological metabolic regulatory hormone in humans? *Int J Obes Relat Metab Disord* 17 Suppl 3:S43–S46
- Ueda T, Oka N, Matsumoto A, Miyazaki H, Ohmura H, Kikuchi T, Nakayama M, Kato S, Imaizumi T 2005 Pheochromocytoma presenting as recurrent hypotension and syncope. *Intern Med* 44:222–227
- Tsujimoto G, Honda K, Hoffman BB, Hashimoto K 1987 Desensitization of postfunctional  $\alpha$  1- and  $\alpha$  2-adrenergic receptor-mediated vasopressor responses in rat harboring pheochromocytoma. *Circ Res* 61:86–98
- Tsujimoto G, Manger WM, Hoffman BB 1984 Desensitization of  $\beta$ -adrenergic receptors by pheochromocytoma. *Endocrinology* 114:1272–1278
- Bravo EL, Tagle R 2003 Pheochromocytoma: state-of-the-art and future prospects. *Endocr Rev* 24:539–553
- Kinney MA, Narr BJ, Warner MA 2002 Perioperative management of pheochromocytoma. *J Cardiothorac Vasc Anesth* 16:359–369
- Prys-Roberts C 2000 Pheochromocytoma—recent progress in its management. *Br J Anaesth* 85:44–57
- Prys-Roberts C, Farndon JR 2002 Efficacy and safety of doxazosin for perioperative management of patients with pheochromocytoma. *World J Surg* 26:1037–1042
- Proye C, Thevenin D, Cecat P, Petillot P, Carnaille B, Verin P, Sautier M, Racadot N 1989 Exclusive use of calcium channel blockers in preoperative and intraoperative control of pheochromocytomas: hemodynamics and free catecholamine assays in ten consecutive patients. *Surgery* 106:1149–1154
- Young Jr WF 1997 Pheochromocytoma: issues in diagnosis, treatment. *Compr Ther* 23:319–326
- van der Horst-Schrivers AN, Kerstens MN, Wolffenbuttel BH 2006 Preoperative pharmacological management of pheochromocytoma. *Neth J Med* 64:290–295
- Brauckhoff M, Gimm O, Dralle H 2004 Preoperative and surgical therapy in sporadic and familial pheochromocytoma. *Front Horm Res* 31:121–144
- Sibal L, Jovanovic A, Agarwal SC, Peaston RT, James RA, Lennard TW, Bliss R, Batchelor A, Perros P 2006 Pheochromocytomas presenting as acute crises after  $\beta$  blockade therapy. *Clin Endocrinol (Oxf)* 65:186–190
- Sloand EM, Thompson BT 1984 Propranolol-induced pulmonary edema and shock in a patient with pheochromocytoma. *Arch Intern Med* 144:173–174
- Eigelberger MS, Duh QY 2001 Pheochromocytoma. *Curr Treat Options Oncol* 2:321–329
- Shapiro B, Fig L 1989 Management of pheochromocytoma. *Endocrinol Metab Clin North Am* 18:443–481
- Williams DT, Dann S, Wheeler MH 2003 Pheochromocytoma—views on current management. *Eur J Surg Oncol* 29:483–490
- Manger WM, Gifford Jr RW 1993 Pheochromocytoma: current diagnosis and management. *Cleve Clin J Med* 60:365–378
- Mannelli M 2006 Management and treatment of pheochromocytomas and paragangliomas. *Ann NY Acad Sci* 1073:405–416
- Malchoff CD, MacGillivray D, Shichman S 2004 Pheochromocytoma treatment. In: Mansoor GA, ed. Secondary hypertension. Totowa, NJ: Humana Press; 235–249
- Boutros AR, Bravo EL, Zanettin G, Straffon RA 1990 Perioperative management of 63 patients with pheochromocytoma. *Cleve Clin J Med* 57:613–617
- Chew SL 2004 Recent developments in the therapy of pheochromocytoma. *Expert Opin Investig Drugs* 13:1579–1583
- Jankovic RJ, Konstantinovic SM, Milic DJ, Mihailovic DS, Stosic BS 2007 Can a patient be successfully prepared for pheochromocytoma surgery in three days? A case report. *Minerva Anestesiol* 73:245–249
- Russell WJ, Metcalfe IR, Tonkin AL, Frewin DB 1998 The preoperative management of pheochromocytoma. *Anaesth Intens Care* 26:196–200

42. Hack HA, Brown TC 1999 Preoperative management of pheochromocytoma—a paediatric perspective. *Anaesth Intensive Care* 27:112–113
43. Nicholson Jr JP, Vaughn Jr ED, Pickering TG, Resnick LM, Artusio J, Kleiner HD, Lopez-Overjero JA, Laragh JH 1983 Pheochromocytoma and prazosin. *Ann Intern Med* 99:477–479
44. Cubeddu LX, Zarate NA, Rosales CB, Zschaek DW 1982 Prazosin and propranolol in preoperative management of pheochromocytoma. *Clin Pharmacol Ther* 32:156–160
45. Kocak S, Aydintug S, Canakci N 2002  $\alpha$  Blockade in preoperative preparation of patients with pheochromocytomas. *Int Surg* 87:191–194
46. Hull CJ 1986 Pheochromocytoma. Diagnosis, preoperative preparation and anaesthetic management. *Br J Anaesth* 58:1453–1468
47. Goldstein RE, O'Neill Jr JA, Holcomb 3rd GW, Morgan 3rd WM, Neblett 3rd WW, Oates JA, Brown N, Nadeau J, Smith B, Page DL, Abumrad NN, Scott Jr HW 1999 Clinical experience over 48 years with pheochromocytoma. *Ann Surg* 229:755–764; discussion 764–756
48. Samaan NA, Hickey RC, Shutts PE 1988 Diagnosis, localization, and management of pheochromocytoma. Pitfalls and follow-up in 41 patients. *Cancer* 62:2451–2460
49. Stenstrom G, Haljamae H, Tisell LE 1985 Influence of pre-operative treatment with phenoxybenzamine on the incidence of adverse cardiovascular reactions during anaesthesia and surgery for pheochromocytoma. *Acta Anaesthesiol Scand* 29:797–803
50. Plouin PF, Duclos JM, Soppelsa F, Boulblil G, Chatellier G 2001 Factors associated with perioperative morbidity and mortality in patients with pheochromocytoma: analysis of 165 operations at a single center. *J Clin Endocrinol Metab* 86:1480–1486
51. Ulchaker JC, Goldfarb DA, Bravo EL, Novick AC 1999 Successful outcomes in pheochromocytoma surgery in the modern era. *J Urol* 161:764–767
52. Newell KA, Prinz RA, Brooks MH, Glisson SN, Barbato AL, Freeark RJ 1988 Plasma catecholamine changes during excision of pheochromocytoma. *Surgery* 104:1064–1073
53. Yabe R, Suenaga K, Niimura S, Itoh N, Tani M, Kunii N, Watari H, Yatabe Y, Mizuno K, Fukuchi S 1987 Treatment of pheochromocytoma with dilevalol. *J Med* 18:147–152
54. Van Stratum M, Levarlet M, Lambilliotte JP, Lignani H, de Rood M 1983 Use of labetalol during anesthesia for pheochromocytoma removal. *Acta Anaesthesiol Belg* 34:233–240
55. Reach G, Thibonnier M, Chevillard C, Corvol P, Milliez P 1980 Effect of labetalol on blood pressure and plasma catecholamine concentrations in patients with pheochromocytoma. *Br Med J* 280:1300–1301
56. Kanto J 1985 Current status of labetalol and other agents that block both  $\alpha$ - and  $\beta$ -blocking agents. *Int J Clin Pharmacol Ther Toxicol* 23:617–628
57. Briggs RS, Birtwell AJ, Pohl JE 1978 Hypertensive response to labetalol in pheochromocytoma. *Lancet* 1:1045–1046
58. Keiser HR 2001 Pheochromocytoma and related tumors. In: DeGroot LJ, Jameson JL, eds. *Endocrinology*. 4th ed. Philadelphia: W.B. Saunders Co.; 1862–1883
59. Solanki KK, Bomanji J, Moyes J, Mather SJ, Trainer PJ, Britton KE 1992 A pharmacological guide to medicines which interfere with the biodistribution of radiolabelled meta-iodobenzylguanidine (MIBG). *Nucl Med Commun* 13: 513–521
60. Takahashi S, Nakai T, Fujiwara R, Kutsumi Y, Tamai T, Miyabo S 1989 Effectiveness of long-acting nifedipine in pheochromocytoma. *Jpn Heart J* 30:751–757
61. Serfas D, Shoback DM, Lorell BH 1983 Pheochromocytoma and hypertrophic cardiomyopathy: apparent suppression of symptoms and noradrenaline secretion by calcium-channel blockade. *Lancet* 2:711–713
62. Bravo EL 2001 Pheochromocytoma. *Cardiol Rev* 10:44–50
63. Sjoerdsma A, Engelman K, Spector S, Udenfriend S 1965 Inhibition of catecholamine synthesis in man with  $\alpha$ -methyl-tyrosine, an inhibitor of tyrosine hydroxylase. *Lancet* 2:1092–1094
64. Brogden RN, Heel RC, Speight TM, Avery GS 1981  $\alpha$ -Methyl-p-tyrosine: a review of its pharmacology and clinical use. *Drugs* 21:81–89
65. Kuchel O, Buu NT, Edwards DJ 1990 Alternative catecholamine pathways after tyrosine hydroxylase inhibition in malignant pheochromocytoma. *J Lab Clin Med* 115:449–453
66. Steinsapir J, Carr AA, Prisant LM, Bransome Jr ED 1997 Metyrosine and pheochromocytoma. *Arch Intern Med* 157:901–906
67. Perry R, Keiser H, Norton J, Wall R, Robertson C, Travis W, Pass H, Walther M, Linehan W 1990 Surgical management of pheochromocytoma with the use of metyrosine. *Ann Surg* 212:621–628
68. Robinson RG, DeQuattro V, Grushkin CM, Lieberman E 1977 Childhood pheochromocytoma: treatment with  $\alpha$  methyl tyrosine for resistant hypertension. *J Pediatr* 91:143–147
69. Pacak K, Linehan WM, Eisenhofer G, Walther MM, Goldstein DS 2001 Recent advances in genetics, diagnosis, localization, and treatment of pheochromocytoma. *Ann Intern Med* 134:315–329
70. Sand J, Salmi J, Saaristo J, Auvinen O 1997 Preoperative treatment and survival of patients with pheochromocytomas. *Ann Chir Gynaecol* 86:230–232
71. Graham GW, Unger BP, Coursin DB 2000 Perioperative management of selected endocrine disorders. *Int Anesthesiol Clin* 38:31–67
72. Balabaud-Pichon V, Bopp P, Levy F, Thiranos JC, Steib A 2002 Excision of adrenal pheochromocytoma and coronary artery bypass graft surgery with cardiopulmonary bypass. *J Cardiothorac Vasc Anesth* 16:344–346
73. Kebebew E, Duh QY 1998 Benign and malignant pheochromocytoma: diagnosis, treatment, and follow-up. *Surg Oncol Clin N Am* 7:765–789
74. Werbel SS, Ober KP 1995 Pheochromocytoma. Update on diagnosis, localization, and management. *Med Clin North Am* 79:131–153
75. Cohen DL, Fraker D, Townsend RR 2006 Lack of symptoms in patients with histologic evidence of pheochromocytoma: a diagnostic challenge. *Ann NY Acad Sci* 1073:47–51
76. Eisenhofer G, Rivers G, Rosas A, Quezado Z, Manger WM, Pacak K, Unmasking a pheochromocytoma by drug therapy: incidence, prevention and management. *Drug Safety*, in press
77. 1989 Food interacting with MAO inhibitors. *Med Lett Drugs Ther* 31:11
78. Eisenhofer G, Goldstein DS, Walther MM, Friberg P, Lenders JW, Keiser HR, Pacak K 2003 Biochemical diagnosis of pheochromocytoma: how to distinguish true- from false-positive test results. *J Clin Endocrinol Metab* 88: 2656–2666
79. Devaux B, Lentschener C, Jude N, Valensi L, Pili-Floury S, Dousset B, Ozier Y 2004 Predictive value of preoperative transthoracic echocardiography in patients undergoing adrenalectomy for pheochromocytoma. *Acta Anaesthesiol Scand* 48:711–715
80. Meune C, Bertherat J, Dousset B, Jude N, Bertagna X, Duboc D, Weber S 2006 Reduced myocardial contractility assessed by tissue Doppler echocardiography is associated with increased risk during adrenal surgery of patients with pheochromocytoma: report of a preliminary study. *J Am Soc Echocardiogr* 19:1466–1470
81. Grosse H, Schroder D, Schober O, Hausen B, Dralle H 1990 The importance of high-dose  $\alpha$ -receptor blockade for blood volume and hemodynamics in pheochromocytoma. *Anaesthesist* 39:313–318
82. Mukherjee JJ, Peppercorn PD, Reznick RH, Patel V, Kaltsas G, Besser M, Grossman AB 1997 Pheochromocytoma: effect of nonionic contrast medium in CT on circulating catecholamine levels. *Radiology* 202:227–231
83. Bessell-Browne R, O'Malley ME 2007 CT of pheochromocytoma and paraganglioma: risk of adverse events with i.v. administration of nonionic contrast material. *AJR Am J Roentgenol* 188:970–974
84. Hack HA 2000 The perioperative management of children with pheochromocytoma. *Paediatr Anaesth* 10:463–476
85. Ellison GT, Mansberger JA, Mansberger Jr AR 1988 Malignant recurrent pheochromocytoma during pregnancy: case report and review of the literature. *Surgery* 103:484–489
86. Pacak K, Keiser HR, Eisenhofer G 2006 Pheochromocytoma. In: DeGroot LJ, Jameson JL, eds. *Endocrinology*. 5th ed. Philadelphia: Elsevier Saunders; 2501–2534

JCEM is published monthly by The Endocrine Society (<http://www.endo-society.org>), the foremost professional society serving the endocrine community.