



A shorter loop in Roux-Y hepatojejunostomy reconstruction for choledochal cysts is equally effective: preliminary results of a prospective randomized study

Mei Diao^a, Long Li^{a,*}, Jin-Zhe Zhang^b, Wei Cheng^{c,*}

^aDepartment of Pediatric Surgery, Capital Institute of Pediatrics, Beijing, PR 100020, China

^bDepartment of Pediatric Surgery, Beijing Children's Hospital, Beijing, PR 100045, China

^cDepartment of Paediatric Surgery, Monash Medical Center, Departments of Paediatrics and Surgery, Faculty of Medicine, Nursing and Health Sciences, Monash University, Clayton, Victoria 3168, Australia

Received 7 October 2009; revised 22 December 2009; accepted 23 December 2009

Key words:

Roux-Y
hepatojejunostomy;
Choledochal cyst;
Children intestinal
obstruction;
Reflux

Abstract

Background: Conventionally, an adult's standard of a 40-cm loop is adopted in Roux-Y hepatojejunostomy (RYHJ) in choledochal cyst (CDC) in children, irrespective of patient size. The redundant length of the jejunal limb may lead to complications. We compared the outcome of an individualized short Roux loop with the standard loop length in RYHJ in children with CDC.

Methods: Two hundred eighteen children with CDC undergoing laparoscopic RYHJ were prospectively randomized into 2 groups: (1) conventional group (CG; n = 108) where a standard 35–40 cm Roux-loop length was used regardless of the child's size and (2) short loop group (SLG; n = 110) in which the Roux-loop length was based on the distance between hepatic hilum and umbilicus. Ultrasonography, upper gastrointestinal contrast studies, and laboratory tests were conducted during the follow-up period.

Results: The mean Roux-loop length of SLG was significantly shorter than that of CG (Student *t* test, $P < .05$). There was no significant difference between the 2 groups in age, operative blood loss, operative time, postoperative hospital stay, and duration of drainage. In CG, 2 of (1.8%) 108 patients developed Roux-loop obstruction, whereas none was detected in SLG (0%). Mild reflux was detected in 2 CG patients and 1 SLG patient 1 month postoperatively, all of which subsided 6 months later. No episodes of cholangitis were observed in either group.

Conclusions: An individualized short Roux-loop length in RYHJ is as effective as the conventional Roux-loop length.

© 2010 Elsevier Inc. All rights reserved.

* Corresponding authors. Long Li is to be contacted at Department of Pediatric Surgery, Capital Institute of Pediatrics, Beijing, PR China. Wei Cheng, Department of Paediatric Surgery, Monash Medical Centre, Southern Health, Departments of Paediatrics and Surgery, Faculty of Medicine, Nursing and Health Sciences, Monash University, Victoria, Australia.

E-mail addresses: lilong22@hotmail.com (L. Li), wei.cheng@med.monash.edu.au (W. Cheng).

Although most surgeons now individualize the length of the Roux loop according to the age and size of the child who is undergoing excision of a choledochal cyst (CDC), there are still some who routinely use the standard 40-cm adult measurement. The Roux loop therefore tends to be unnecessarily long, especially in infants and young children [1]. It may lead to complications including intestinal

obstruction [2], bile stasis [3], and bacterial overgrowth and associated ascending cholangitis [4], stone formation, and malabsorption of fat and fat-soluble vitamins [5]. We compared the outcome of a shorter Roux loop with the standard loop length in Roux-Y hepatojejunostomy (RYHJ) reconstruction in children with CDC.

1. Methods

From October 2001 to October 2009, 218 children with CDC in our center who were operated on by the same surgeon using a complete laparoscopic cyst excision and RYHJ technique were prospectively studied. There were 56 boys and 162 girls. The mean age was 4.16 years, with a range of 7 days to 18 years. Ethical approval from the Ethics Committee of the Capital Institute of Pediatrics was obtained. Written informed consent was obtained from the parents before entry into the study. On admission, patients were randomized into 2 groups according to a computer-generated list of random numbers provided by a researcher: (1) the conventional group (CG; $n = 108$) where a standard 35- to 40-cm Roux loop length was used regardless of the child's size and (2) the short loop group (SLG; $n = 110$) where the Roux loop length was based on the distance between hepatic hilum and umbilicus. All patients were followed up in the clinic at 1, 3, 6, and 12 months postoperatively and at 6-month intervals thereafter. Physical examination, abdominal ultrasonography, and laboratory tests were carried out at each visit. Upper gastrointestinal contrast studies were performed at 1, 6, and 12 months of follow-up. Age, operative blood loss, operative time, postoperative hospital stay, duration of drainage, postoperative complications, and preoperative and postoperative laboratory values were evaluated. The reflux was classified into 4 grades: grade 0: no reflux into the Roux loop; grade I: mild reflux below the level of transverse colon; grade II: moderate reflux above the level of transverse colon but below the level of hepatic hilum; and grade III: severe reflux into intrahepatic bile ducts.

Data were analyzed with SPSS 13.0 package. Student *t* tests were used in comparison of age, operative blood loss, operative time, postoperative hospital stay, duration of abdominal drainage, and preoperative and postoperative laboratory values between 2 groups; χ^2 tests were applied to compare the morbidity of postoperative complications between 2 groups. Paired *t* tests were performed to compare preoperative and postoperative laboratory values in both groups, $P < .05$ was considered being statistically significant.

2. Results

One hundred eight patients (49.5%) were randomized into the CG, whereas the remaining 110 patients (50.4%) were randomized into the SLG. The mean (SD) length of Roux loop in the SLG was 20.81 (4.07) cm (range, 14-25 cm),

which was significantly shorter than 35.87 (3.91) cm (range, 30-40 cm) in the CG (Student *t* test, $P < .001$). The median follow-up period was 38 months (range, 6-94 months). There were no significant differences observed between the 2 groups in regard to age, operative blood loss, operative time, postoperative hospital stay, and duration of drainage (4.82 ± 4.12 years versus 3.97 ± 3.61 years, 10.05 ± 5.27 mL versus 8.91 ± 3.73 mL, 3.79 ± 1.15 hours versus 3.50 ± 1.06 hours, 8.01 ± 3.97 days versus 7.16 ± 2.40 days, 4.08 ± 2.11 days versus 3.63 ± 1.35 days; $P = .11, .07, .06, .06, .06$, respectively). There was no associated mortality, anastomotic stenosis, cholangitis, or gastrointestinal bleeding noted in either group. In the CG, 2 (1.8%) of 108 patients developed Roux-loop obstruction, and an additional 2 (1.8%) of 108 were complicated by a bile leak, whereas none of these complications were found in the SLG. The overall complication rate of the SLG was lower than that of the CG, but the difference did not reach statistical significance ($P = .152$, respectively). Seventy-six patients in the CG (70.3%) and 78 patients in the SLG (70.9%) underwent upper gastrointestinal contrast studies postoperatively. Grade I reflux was detected in 2 patients from the CG and 1 patient from the SLG 1 month postoperatively. The reflux subsided 6 months later in all 3 patients. The remaining patients in both groups recovered without evidence of reflux (Fig. 1). Postoperative liver function tests and blood amylase levels normalized in both groups ($P < .001$).

3. Discussion

Cyst excision with RYHJ is the standard surgical management for CDC in children. Currently, the length

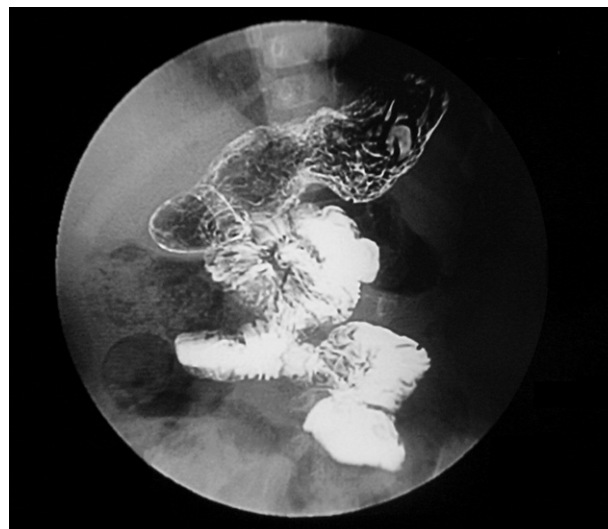


Fig. 1 Postoperative upper gastrointestinal contrast study. A 15.5-cm Roux loop was used in RYHJ for a 3-month-old girl with CDC. No reflux was shown on upper gastrointestinal contrast study at 1-year follow-up.

of the Roux loop is individualized based on the age and size of in children with CDC in most surgical practices, whereas the adult's standard of a 40-cm Roux loop is still routinely applied in some centers [1]. However, the Roux loop tends to be proportionally long. The small bowel length increases significantly with the child's age. The mean length of small intestine is 275 cm at birth (full-term), 380 cm at 1 year of age, 450 cm at 5 years, 500 cm at 10 years, 575 cm at 20 years, and 600 cm in adults [6]. A redundant Roux loop is likely to result in many complications. A long ascending loop can undergo volvulus because of great disparity between the intestinal length and the mesenteric length [2]. Other reported complications include bile stasis [3] and lodging of food particles in the loop. The latter 2 may serve as the nidus for stone formation, leading to bacterial overgrowth and repeated infection [4]. Ectopic gut pacemaker activity may also cause antiperistalsis [3], leading to ascending cholangitis [4]. In addition, bacterial overgrowth increases bile salt loss and may result in steatorrhea [7] with the consequences of malabsorption of fat [5] and fat-soluble vitamins A, D, E, and K. On the other hand, the secretive surface area of gastric inhibitory polypeptide in the remaining functional jejunal segment is remarkably decreased when a long segment of proximal jejunum is used for the Roux loop. Hyposecretion of gastric inhibitory polypeptide induces hypersecretion of gastric acid, which, in turn, may result in duodenal ulcer [8]. These potential complications prompted the performance of the current study. Our results suggest that an individualized short Roux-loop length in hepatojejunostomy reconstruction, which is tailored according to the child's body size, is more appropriate. It is as effective as the conventional 40-cm Roux-loop length. Although some surgeons attempt to individualize the length of the Roux loop according to the age of the patient, there are few studies like the current series that objectively evaluate the outcomes of short loop RYHJ in children with CDC.

It has been argued that lengthening Roux loop could achieve a better antireflux effect [9]. However, comparative studies found the antireflux outcome was not significantly improved by this approach [10]. Our long-term follow-up results in the current study suggest that an individualized short-loop RYHJ provides a comparable antireflux effect compared with the standard loop length RYHJ. Because anastomotic stenosis and biliary tract obstruction are the main contributing mechanisms of postoperative reflux cholangitis, adequate diameter of the anastomotic stoma and prevention of obstruction in the reconstructed biliary tract (eg, kinking of a redundant Roux loop, stones formation, etc) become relatively more important. Even in instances where reflux may occur, the food particles refluxed into intrahepatic bile ducts can drain out easily [11]. Anastomosis diameter ranging from 1.5 to 3.0 cm is

recommended for adult patients, and a transanastomotic stent is recommended if the diameter is less than 1.0 cm [10,12]. Our experience indicates that an anastomotic stoma with diameter of 1.0 to 1.4 cm is adequate for children.

The weakness of the current study is that the duration of follow-up is not long enough. Therefore, the long-term outcomes are not well defined. Further long-term outcome studies would produce more convincing results. In addition, estimation of postoperative fat absorption using the ^{13}C mixed-triglyceride breath test and bile flow assessment by $^{99\text{m}}\text{Tc}$ -HIDA hepatobiliary scintigraphy comparing children with CDC who undergo short-loop RYHJ versus conventional loop RYHJ reconstructions are warranted. Application of short Roux loop in Kasai's operation will be evaluated in future study.

Our experience showed that an individualized, shorter-loop length in RYHJ reconstruction for children with CDC is equally effective as is the conventional 40-cm loop.

References

- [1] Yamataka A, Kobayashi H, Shimotakahara A, et al. Recommendations for preventing complications related to Roux-en-Y hepatico-jejunostomy performed during excision of choledochal cyst in children. *J Pediatr Surg* 2003;38(12):1830-2.
- [2] Wang HZ. Congenital biliary dilatation. In: Li Z, Wang HZ, Ji SJ, editors. *Practical pediatric surgery*. 1st ed. Beijing: The People's Health Publishing House; 2001. p. 1060-75.
- [3] Ducrotte P, Peillon C, Guillemot F, et al. Could recurrent cholangitis after Roux-en-Y hepaticojejunostomy be explained by motor intestinal anomalies? A manometric study. *Am J Gastroenterol* 1991;86(9):1255-8.
- [4] Zhao YW, Huang DH. The relationship between choledochojejunostomy and post-operative cholangitis. Chang Chun: Bai Qiu En Medical University; 1994.
- [5] Suzuki M, Tanaka K, Ohtani K, et al. Estimation of postoperative fat absorption using the ^{13}C mixed-triglyceride breath test in children with choledochal cyst. *Eur J Pediatr* 2009;168(1):35-8.
- [6] Weaver LT, Austin S, Cole TJ. Small intestinal length: a factor essential for gut adaptation. *Gut* 1991;32(11):1321-3.
- [7] De Vriese SR, Savelii JL, Poisson JP, et al. Fat absorption and metabolism in bile duct ligated rats. *Ann Nutr Metab* 2001;45(5):209-16.
- [8] Sato T, Imamura M, Sasaki I, et al. Gastric acid secretion and gastrointestinal hormone release after biliary reconstruction procedures. *Am J Surg* 1983;146(2):245-9.
- [9] Bismuth H, Franco D, Corlette MB, et al. Long term results of Roux-en-Y hepaticojejunostomy. *Surg Gynecol Obstet* 1978;146(2):161-7.
- [10] Liu YB, Peng SY. Causes and treatments for reoperation or multioperation after cholangioenterostomy. *Chin J Pract Surg* 2006;26(3):165-7.
- [11] Qin HQ, Huang LY, Shi ZM. Diagnosis and treatment of post-operative complications of Roux-Y choledochojejunostomy in 46 cases. *Guang Xi J Med* 2001;23(6):1548-9.
- [12] Ma LD, Kong FM. The relationship between different surgical procedures of choledochojejunostomy and biliary tract infection—219 cases reports. *Liao Ning J Med* 2006;20(3):177.